




Skin Conditions in HIV

Joe Caperna, MD, UCSD

Chris Holt, researcher

May 2025

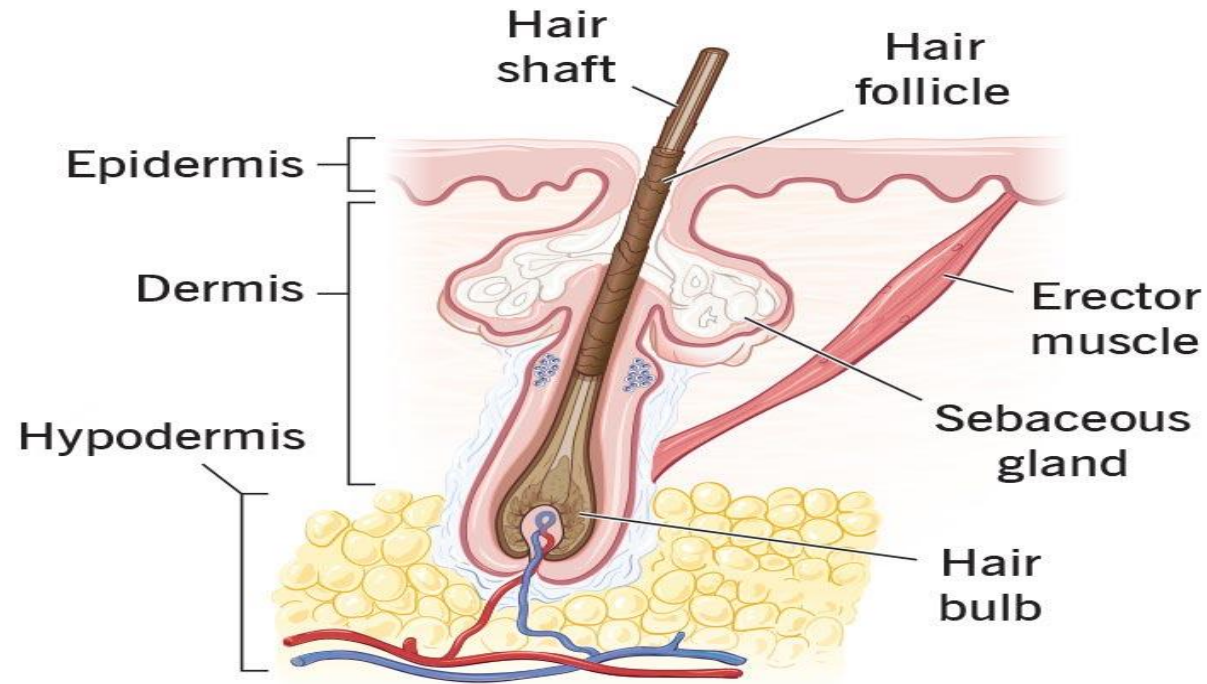


Your integumentary system is your body's outer layer. It's made up of your skin, nails, hair and the glands and nerves on your skin. Your integumentary system acts as a physical barrier — protecting your body from bacteria, infection, injury and sunlight. It also helps regulate your body temperature and allows you to feel skin sensations like hot and cold.

What makes up the integumentary system?

Your integumentary system is an organ that consists of a few main structures: skin, nails, hair and glands, along with the nerves and blood vessels that support them.

Integumentary System




Cleveland
Clinic
©2022

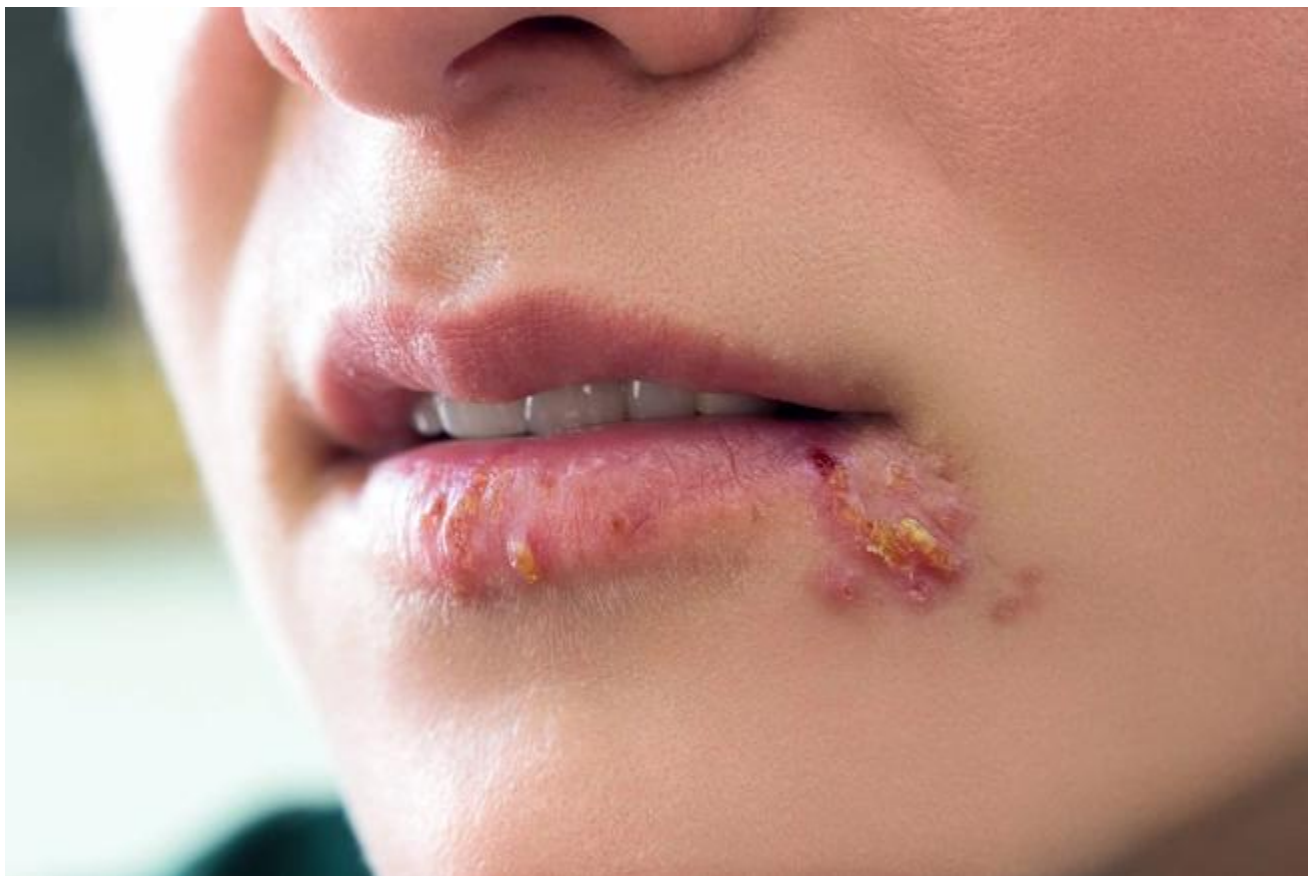Your skin is the largest and heaviest organ in your body. It weighs about six pounds (or more) and is approximately 2 millimeters thick — thinner on sensitive areas like eyelids, and thicker on surfaces that take more stress, like the soles of your feet. One inch of your skin contains nearly 19 million cells.

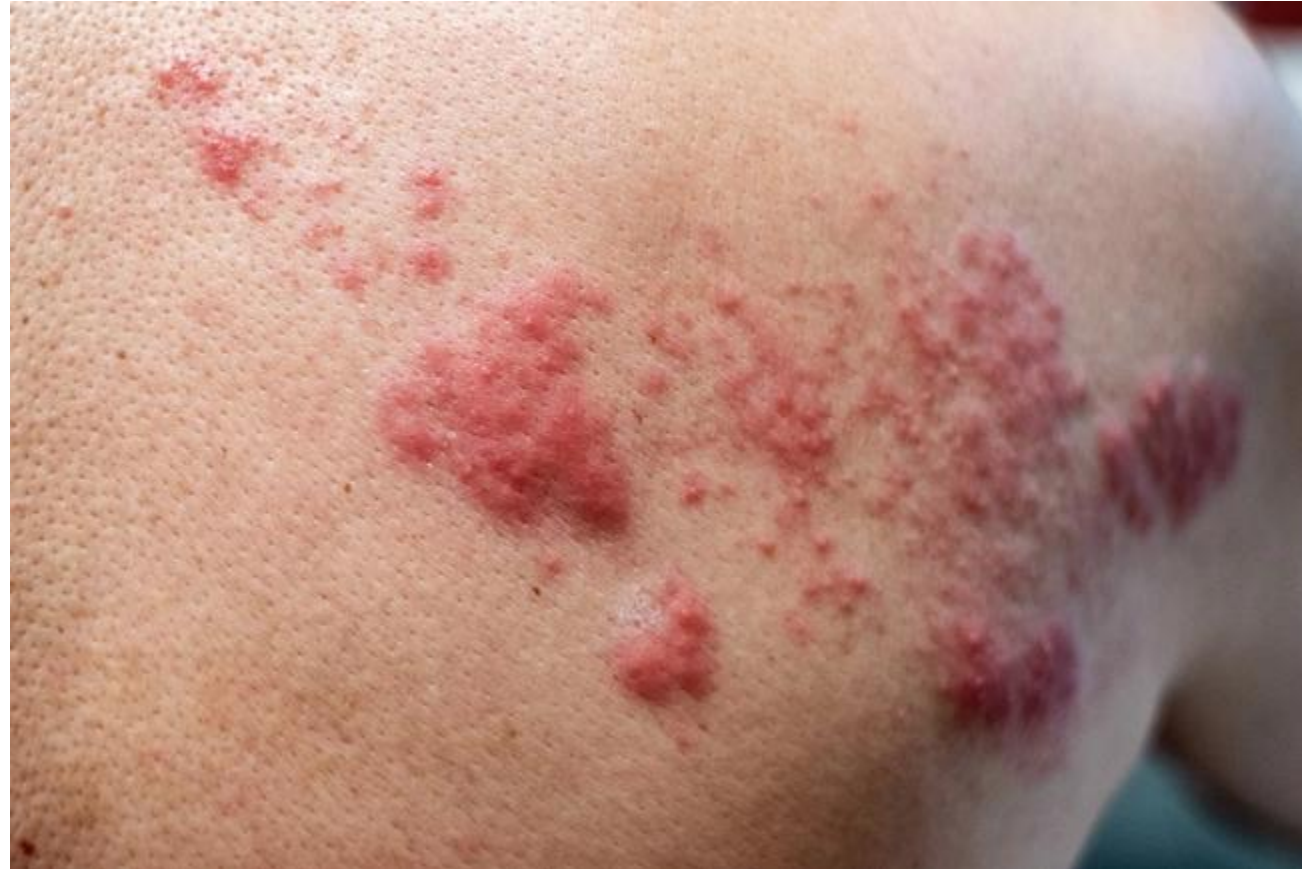Acute HIV

- During the acute HIV infection syndrome (in the first few weeks after initial exposure), patients can develop a symmetrical maculopapular erythematous exanthem that involves the face, palms, soles, trunk, and limbs, in conjunction with systemic viral symptoms. There may also be mucocutaneous ulceration.

Viral Infections

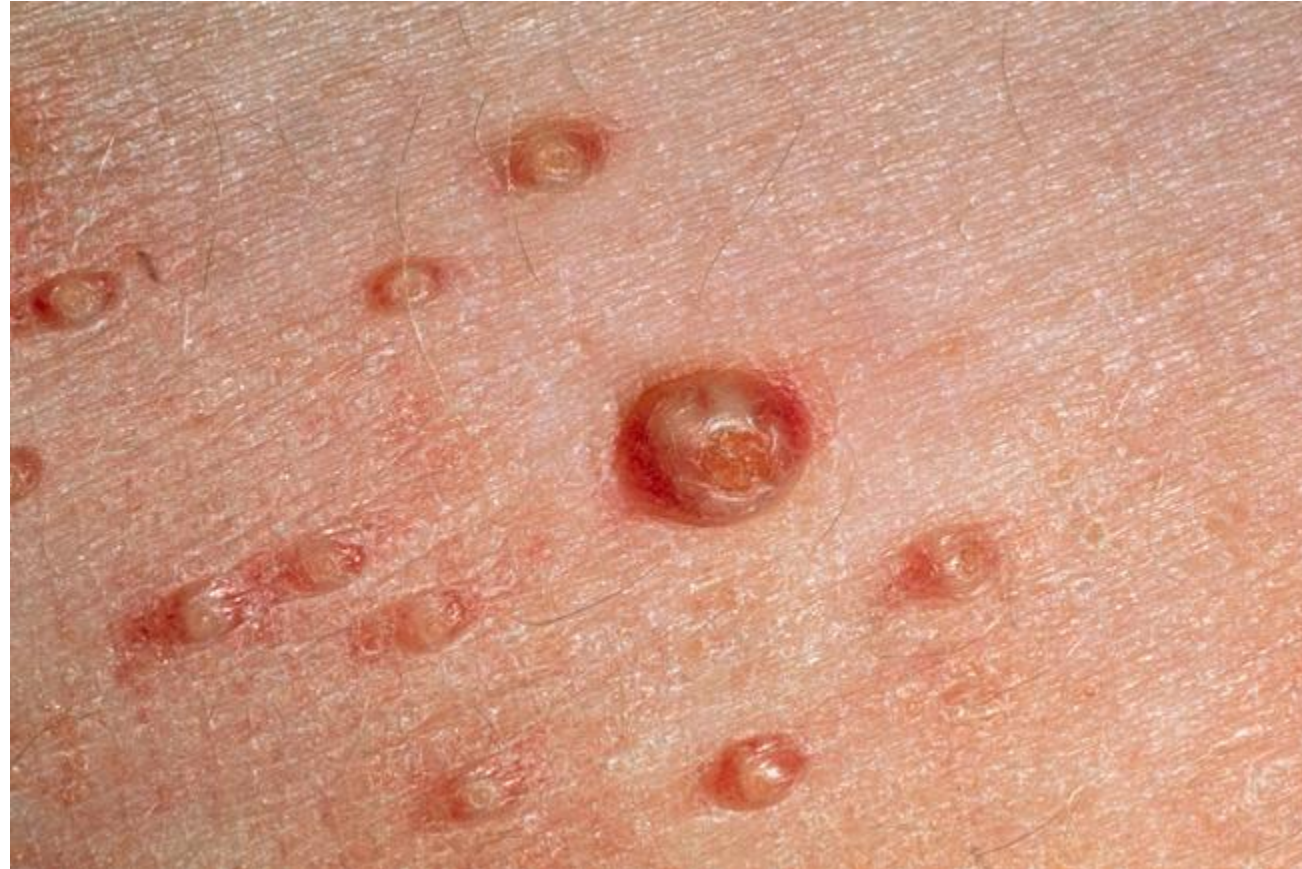- Herpes simplex virus (HSV) is the most common viral infection noted in HIV and is often severe and recurrent. This manifests as small groups of painful vesicles, typically in the facial (lips) or genital region, although can occur at any site. Similarly, varicella zoster virus infection ("shingles") can cause a painful vesicular rash, typically in a dermatomal distribution or as a disseminated rash due to the immunosuppression. This can be persistent and refractory to treatment, causing significant pain.





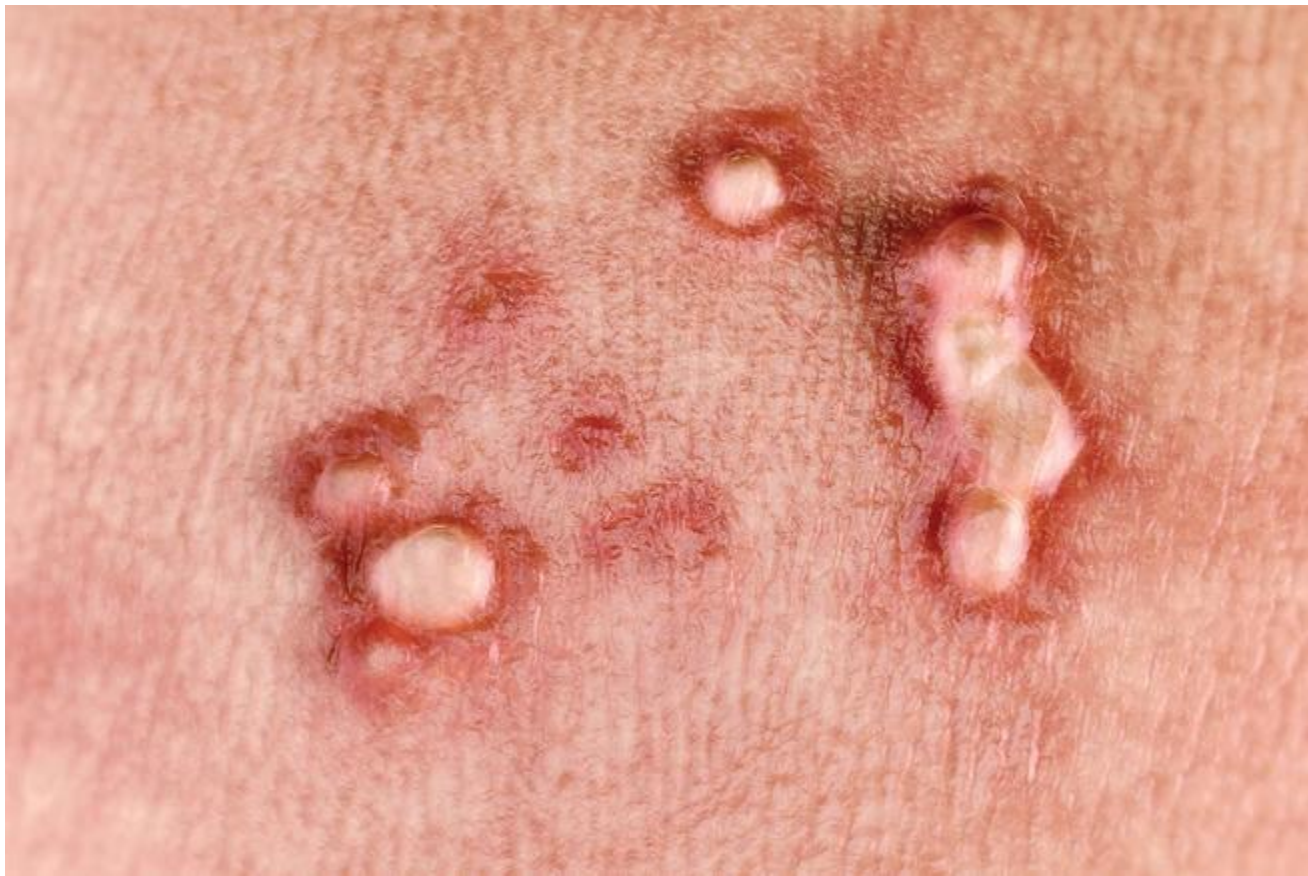Viral Infections

- Molluscum contagiosum infection is caused by a poxvirus, resulting in small, round, skin-colored papules. Although normally a disease seen in children, it is common and seen early in adults with HIV infection. Compared with the general population, those with HIV may develop larger and more numerous lesions, typically over the face and genital area.



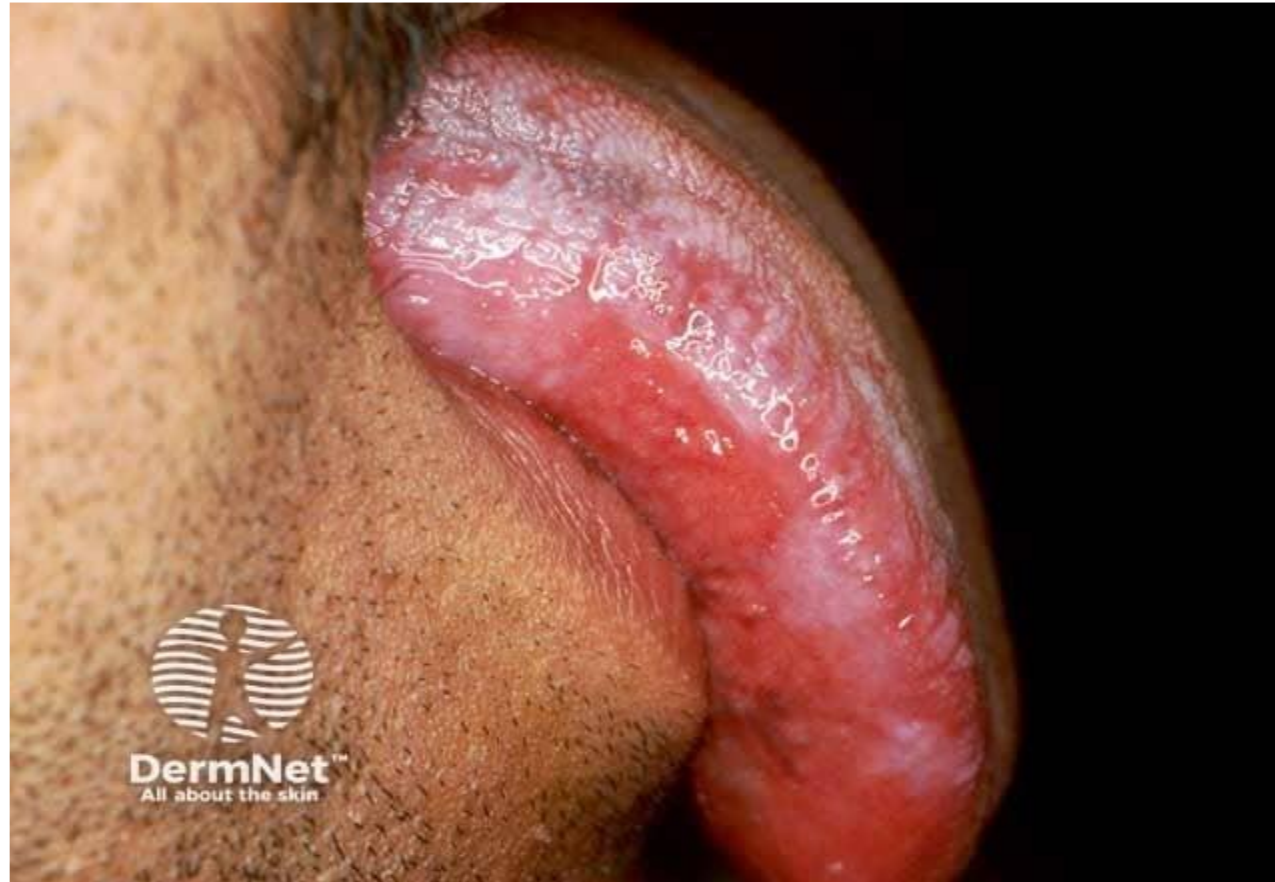Viral Infections

- Human papillomavirus is prevalent in the HIV population and will often persist despite highly active antiretroviral therapy (HAART). As well as producing common and genital warts, and a rare condition called acquired epidermodysplasia verruciformis, the oncogenic nature of the virus gives an increased risk of developing malignancies (particularly oral and rectal). The incidence of malignancy is rising because those with HIV are living longer.



Viral Infections

- Oral hairy leukoplakia is characterized by persistent, asymptomatic white plaques covering the tongue, caused by Epstein-Barr virus. This is seen almost exclusively in immunocompromised people and in HIV infection, typically only at CD4 counts below 200–300micromol/L. It is one of the AIDS-defining diseases.



Fungal Infections

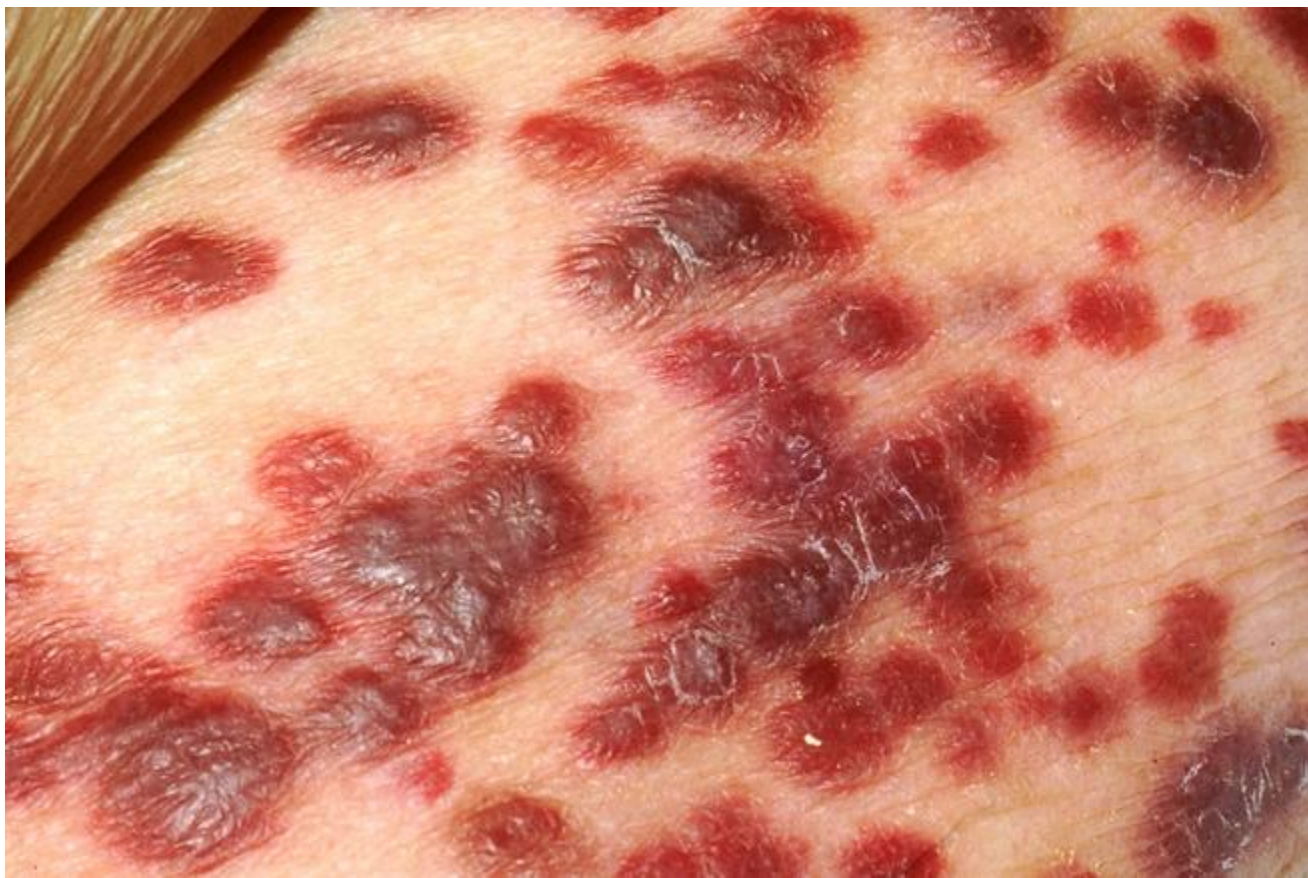- There are a range of fungal infections that occur at different degrees of immunocompromise in HIV. Common presentations such as tinea (of any body area) and onychomycosis and candidal infections can occur early, but are more likely to be severe, atypical in nature, and less responsive to treatment.

Yeast Infections

- Pityrosporum folliculitis and pityriasis versicolor are both conditions caused by *Malassezia* yeasts, commonly found as part of the normal skin microflora. The former produces an acne-like inflammation around the hair follicle, whereas the latter causes hyper or hypo-pigmented lesions over the skin.

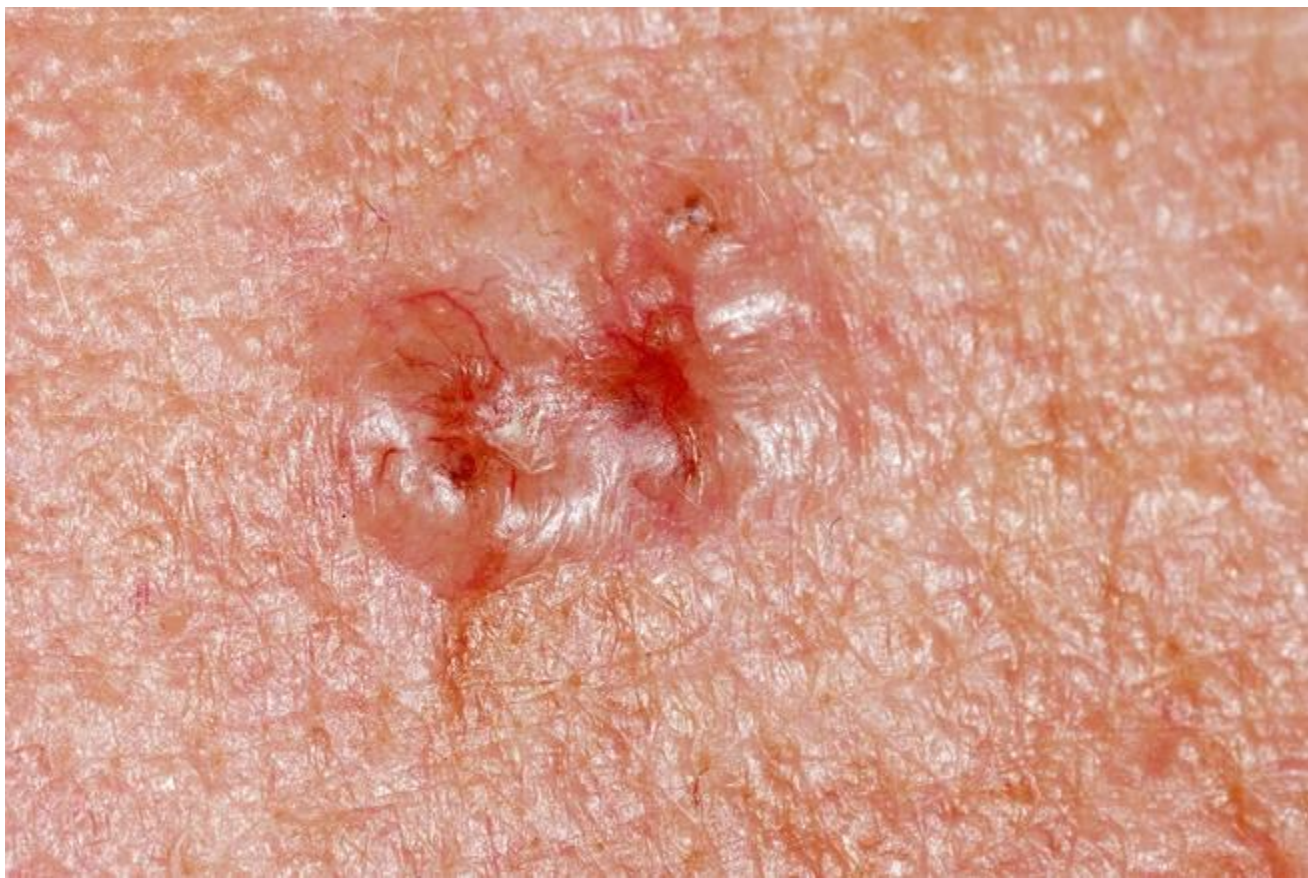Malignancy

- People living with HIV have an increased risk of developing cutaneous malignancies due to their impaired immune response. Prior to widespread treatment with HAART, the AIDS-defining [Kaposi sarcoma](#) was the most prevalent malignancy in the HIV population due to infection by human herpesvirus 8. It typically presents with painless, red-purple lesions anywhere in the body and is more strongly associated with a declining CD4 count.



Malignancy

- There is a 2-fold increased risk of skin [squamous cell carcinoma](#) and [basal cell carcinoma](#) in those with HIV, compared to the general population. Improved CD4 count and HAART do not have a protective benefit against developing these malignancies. There is conflicting data regarding the relationship between HIV and [melanoma](#), however when present there is typically an aggressive course and increased mortality.



Malignancy

- Cutaneous T- and B-cell lymphomas are a diverse disease group also more prevalent with HIV infection.

- Specific cutaneous lymphomas include:

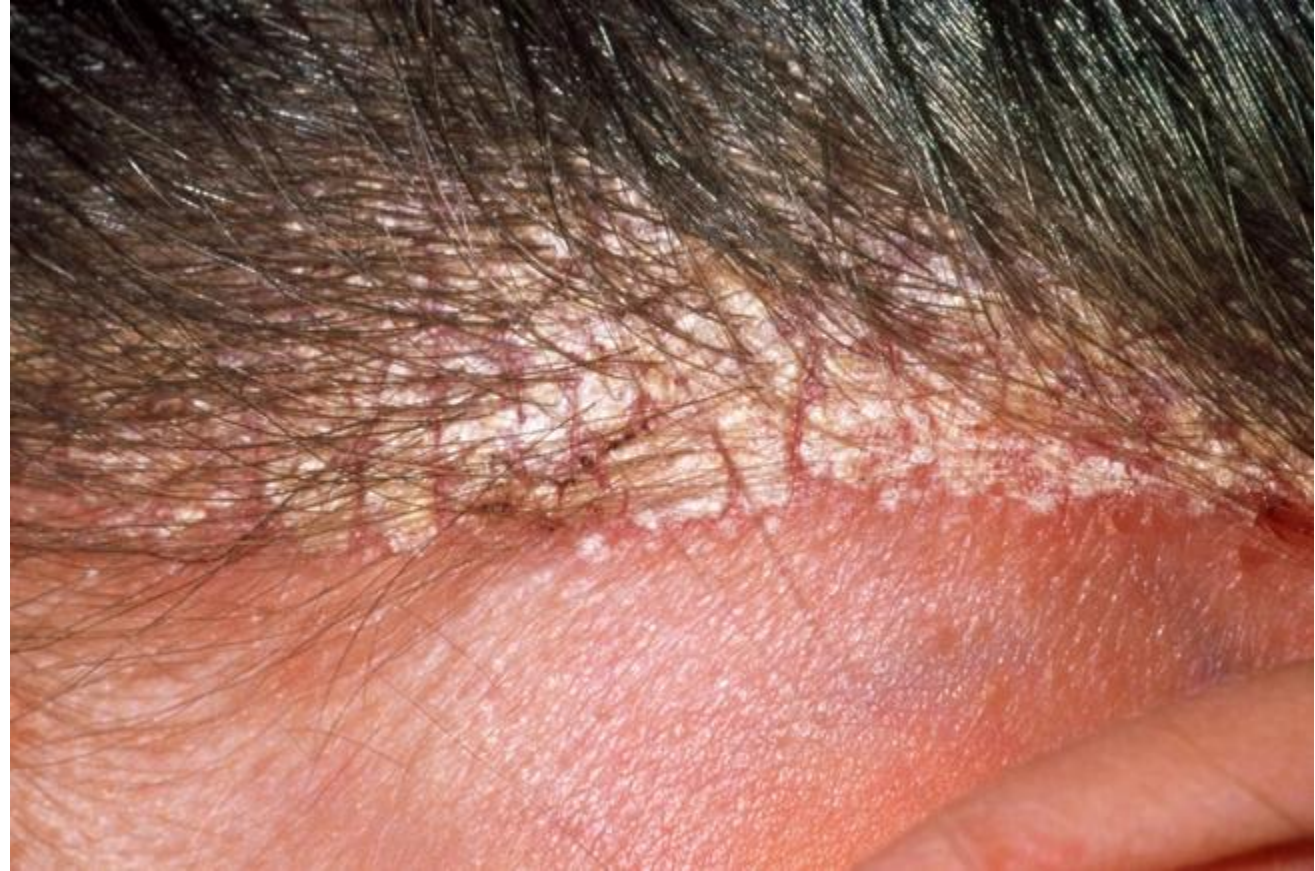Mycosis fungoides

Anaplastic large cell lymphoma

Plasmablastic lymphoma.

Inflammatory

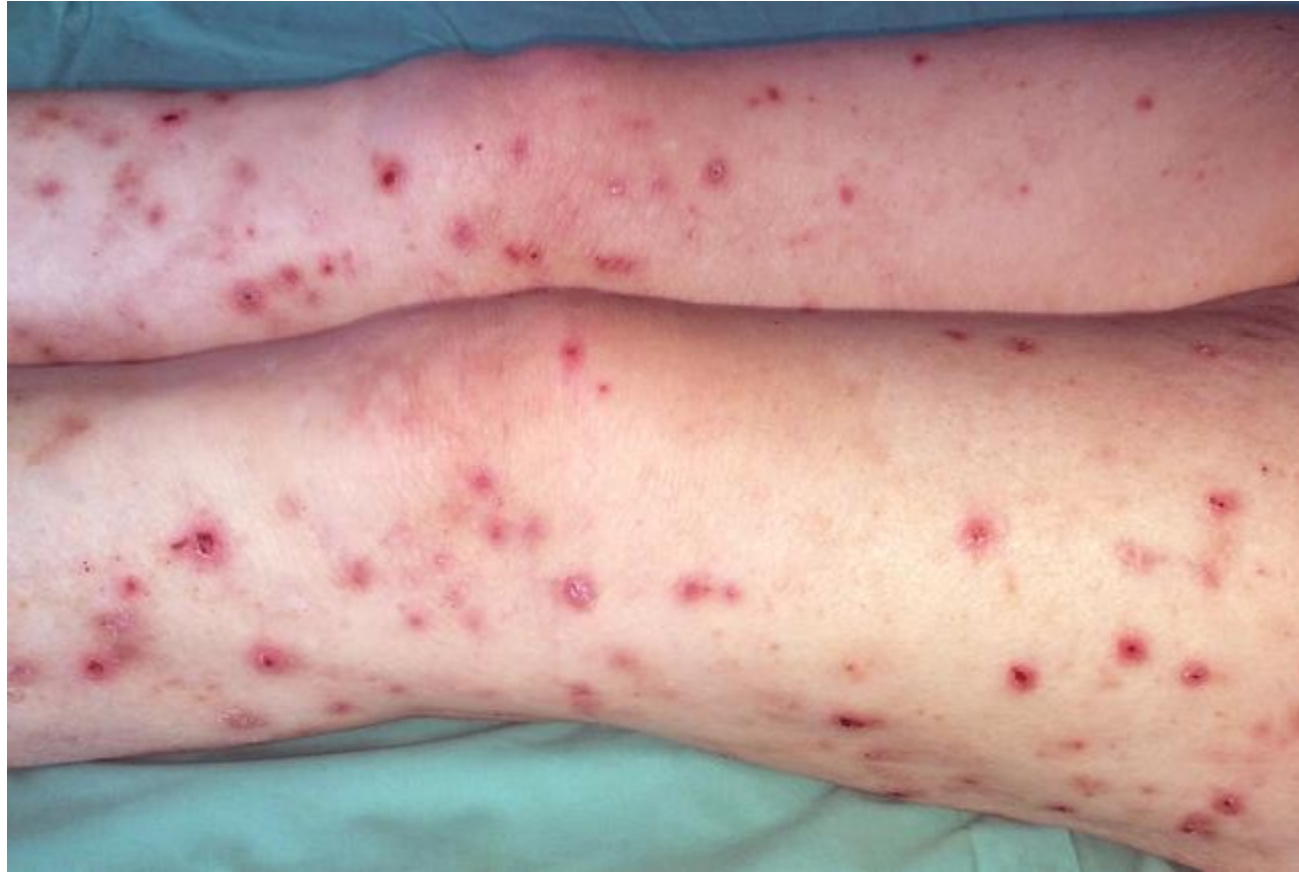- Psoriasis, seborrheic dermatitis, and eczema are common dermatological conditions in the general population. In people living with HIV, they are often more severe, treatment resistant, and likely to become secondarily infected.
- Psoriasis in HIV infection is more likely to present with atypical morphology which can cause diagnostic difficulty. It can worsen acutely and progress to erythroderma with declining immune function.
- Seborrheic dermatitis is the most common skin condition found in people living with HIV, although rates have fallen since widespread HAART implementation. It is often refractory to regular treatment until underlying immune function is improved.



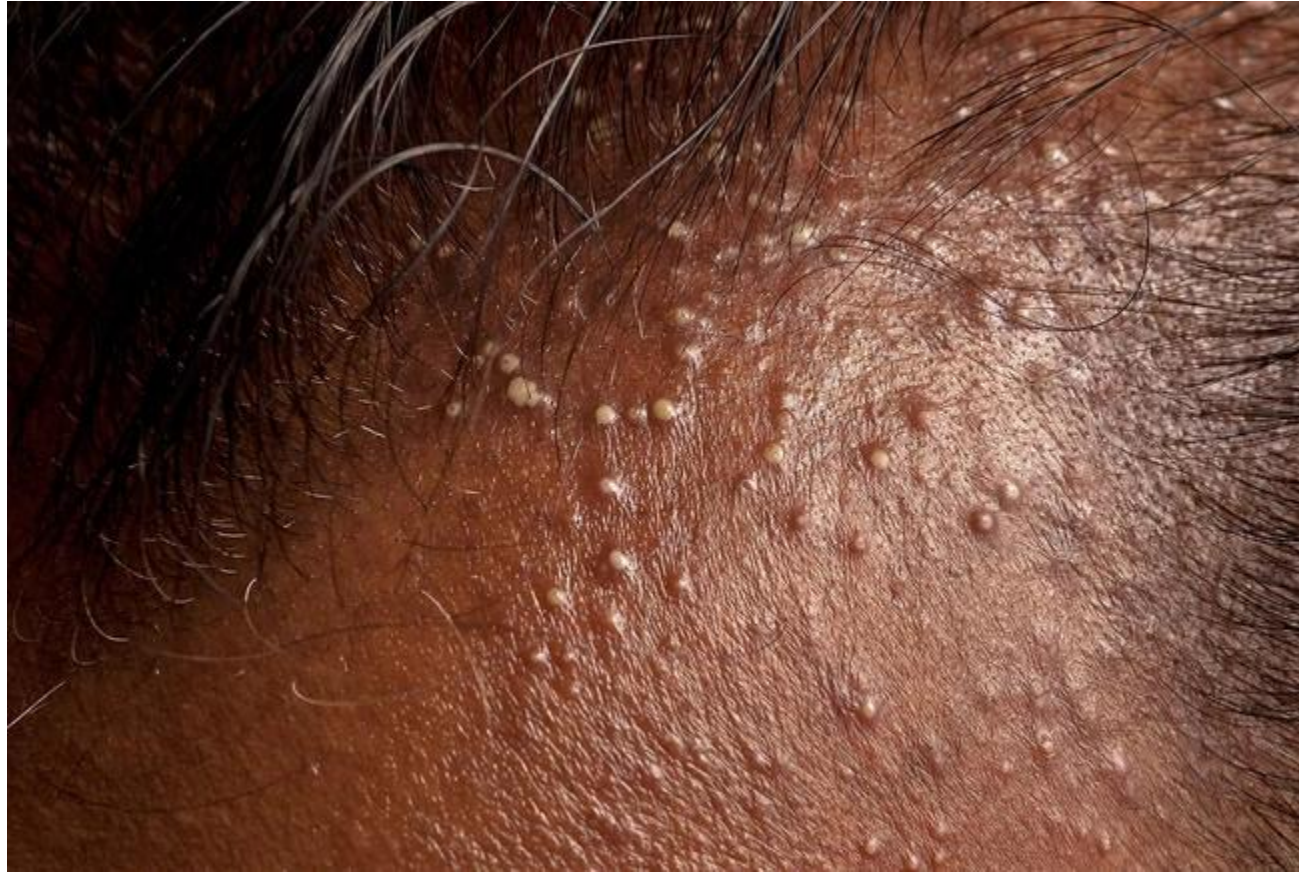Inflammatory

- Pruritic papular eruption and eosinophilic folliculitis are intensely itchy widespread rashes, which occur exclusively in HIV infection. Pruritic papular eruption can often be the first presentation of HIV in an otherwise asymptomatic person. However, eosinophilic folliculitis typically only occurs at CD4 counts of <300 , therefore making it an important diagnostic marker of advanced disease.

Pruritic Papular Eruption



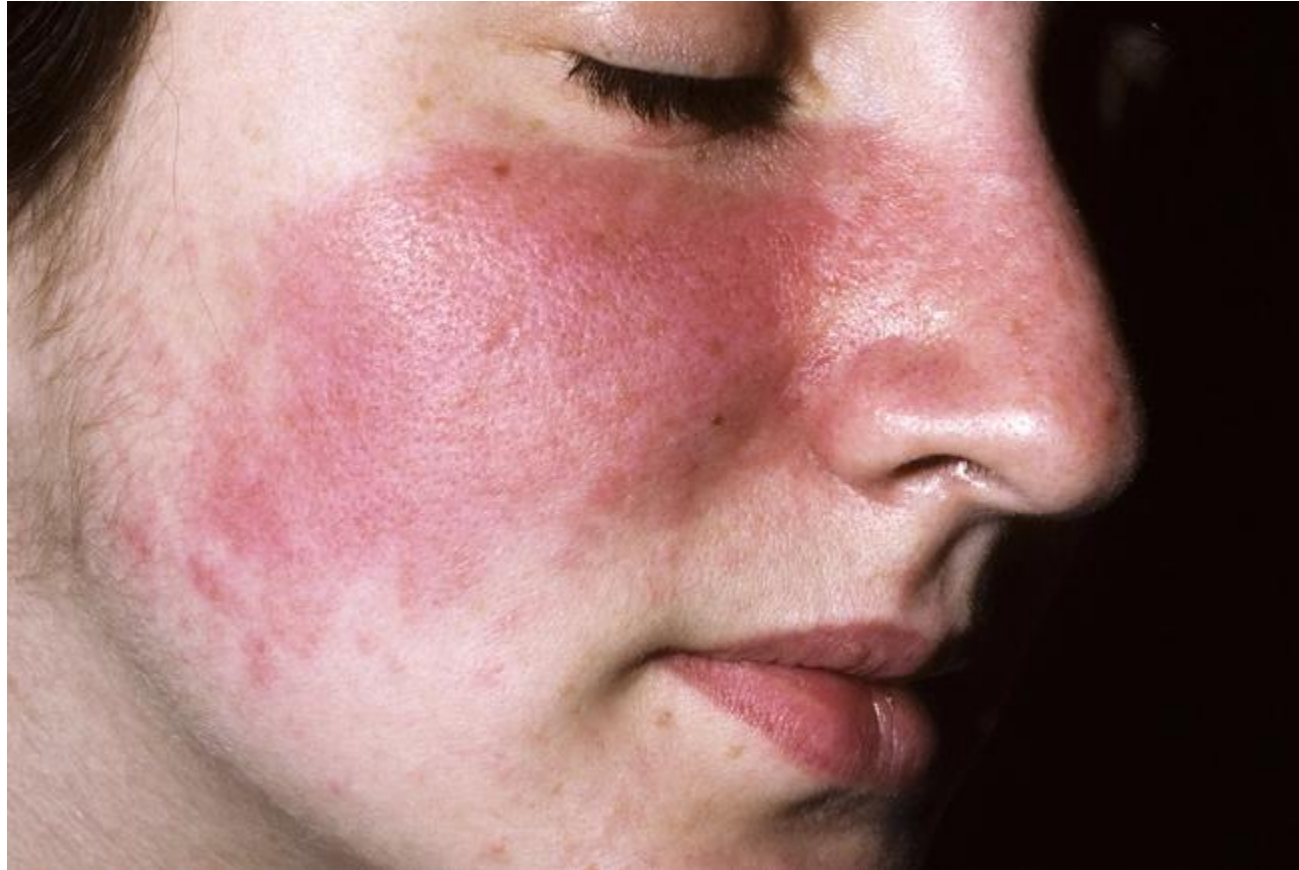Eosinophilic Folliculitis



Misc.

- Cutaneous adverse drug reactions, including morbilloform eruptions, Stevens-Johnson Syndrome (SJS), toxic epidermal necrolysis (TEN), and Drug Rash with Eosinophilia and Systemic Symptoms (DRESS), occur more frequently in HIV infection. This may be related to immune dysfunction and associated polypharmacy, with some antiretrovirals and antibiotics (co-trimoxazole) having particularly high reaction rates.
- Photosensitivity reactions including porphyria cutanea tarda and chronic actinic dermatitis have been described in several HIV patients with advanced disease. The pathophysiology of these associations is poorly understood.
- Lipodystrophy is caused by loss of fat under the skin. It can be due to HIV infection and medication to treat HIV.

Photodermatitis



Mpox

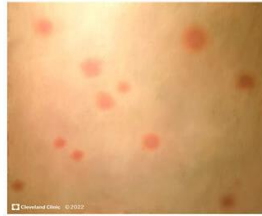- Mpox (previously known as monkeypox) is a disease caused by a virus. It usually causes a rash and flu-like symptoms. The rash is similar to the one caused by a related virus, smallpox.
- Cases of mpox happen regularly (it's endemic) in parts of Africa. But outbreaks sometimes happen in other places around the world. An outbreak is an increase in cases, or a larger-than-expected number of cases.

Mpox rash

- The rash caused by mpox can appear as sores on your mouth, face, hands, feet, penis, vagina or anus. Some people have a widespread rash, but others only have a few bumps or blisters.
- Mpox rash can go through several stages over two to four weeks:
 - It may start out as flat, red bumps. These can be painful.
 - The bumps become raised.
 - The bumps turn into blisters.
 - The blisters fill with pus.
 - The blisters crust over and fall off.

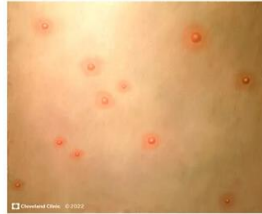Mpox

A visual review of the five stages:



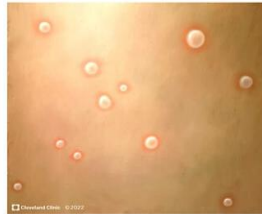Stage 1 – Macule.

The rash starts as flat, red spots (lasts for 1-2 days).



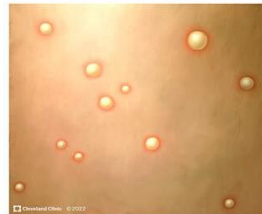Stage 2 – Papule.

The spots become hard, raised bumps (lasts for 1-2 days).



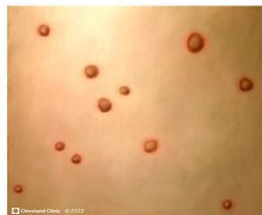Stage 3 – Vesicle.

The bumps get larger. They look like blisters filled with clear fluid (lasts for 1-2 days).



Stage 4 – Pustule.

The blisters fill with pus (lasts for 5-7 days).



Stage 5 – Scabs.

The spots crust over and become scabs that eventually fall off (lasts for 7-14 days).

Mpox Complications

- Complications caused by mpox can include:
- Bacterial infections, which can lead to sepsis.
- Loss of vision or eye damage from mpox ocular infections.
- Myopericarditis (inflammation around your heart).
- Encephalitis (inflammation in your brain).
- Pneumonia.
- Respiratory distress (extreme difficulty breathing and getting oxygen to your body).
- Severe scarring.

Mpox antiviral Treatment Options

- Tecovirimat

Typically the first antiviral considered for patients who need more than supportive care.

- Brincidofovir

An antiviral that can be considered for combination therapy with tecovirimat.

- Vaccinia Immune Globulin (VIGIV)

An antiviral that can be considered for combination therapy with tecovirimat.

- Cidofovir

An antiviral with a similar mechanism of action to brincidofovir.

Mpox Vaccinations

- The virus that causes mpox is related to the virus that causes smallpox. JYNNEOS is a 2-dose vaccine developed to protect against mpox and smallpox.
- People need to get both doses of the vaccine for the best protection against mpox.
- The second dose should be given 4 weeks after the first dose. However, if it has been longer than 4 weeks since you got the first dose, get the 2nd dose as soon as possible.
- Whether or not you've been vaccinated, continue to reduce your risk of getting mpox.

Mpox Vaccination Guidelines

- CDC recommends vaccination if:
- You had known or suspected exposure to someone with mpox
- You had a sex partner in the past 2 weeks who was diagnosed with mpox
- You are a gay, bisexual, or other man who has sex with men or a transgender, nonbinary, or gender-diverse person who in the past 6 months has had any of the following:
- A new diagnosis of one or more sexually transmitted diseases (e.g., chlamydia, gonorrhea, or syphilis)
- More than one sex partner
- You have had any of the following in the past 6 months:
- Sex at a commercial sex venue (like a sex club or bathhouse)
- Sex related to a large commercial event or in a geographic area (city or county for example) where mpox virus transmission is occurring
- You have a sex partner with any of the above risks
- You anticipate experiencing any of the above scenarios
- If you are traveling to a country with a clade I mpox outbreak and anticipate any of the following activities during travel, regardless of gender identity or sexual orientation:
- Sex with a new partner
- Sex at a commercial sex venue (e.g., a sex club or bathhouse)
- Sex in exchange for money, goods, drugs, or other trade
- Sex in association with a large public event (e.g., a rave, party, or festival)
- You are at risk for occupational exposure to orthopoxviruses (e.g., certain people who work in a laboratory or a healthcare facility).

Dr Michelle Pelle, MD, <https://meddderm.net/>


Skin conditions more common in people living with HIV, >90%

1. The importance of a routine full skin exam
2. Skin cancer prevention with sun block, especially in the car
3. Mineral preferred over chemical sunblock
4. of Voltaren© gel, an anti-inflammatory drug, for treating precancers and non-melanoma skin cancers
5. Stay hydrated for healthy skin

Lecture details:

1. The importance of a routine full skin exam
2. Skin cancer prevention with sun block, especially in the car
3. Mineral preferred over chemical sunblock
4. of Voltaren© gel, an anti-inflammatory drug, for treating precancers and non-melanoma skin cancers
5. Stay hydrated for healthy skin

ACT HIV 3 May 2025 Chicago

- Dr Toby Mauer, MD, Indiana University, UCSF Prof emeritus
- pdf:  Skin-HIV 2025-05-03_Maurer_Toby.pdf
- [Ppt link](#)
- Minoxidil for hair loss,
 - same dose male or female
 - 5mg once daily, and
 - need several or more months for hair regrowth on head.